

CASE REPORT

Helen James,¹ B.D.S. and Giacomo N. Cirillo,¹ B.D.S.

Bite Mark or Bottle Top?

ABSTRACT: An alleged assault was reported by a 42-year-old female, with initial medical examination revealing an apparent bite mark on the right buttock. Odontological examination, including visual assessment, full history and photographs showed that the injury did not meet the class characteristics of a human bite. Subsequent digital overlay production showed that the injury pattern was consistent with a corrugated bottle top. This case highlights the need for careful assessment of injuries alleged to be caused by human teeth.

KEYWORDS: forensic science, forensic odontology, bite mark, differential diagnosis, bottle top, digital overlay

A bite mark may be caused by the teeth alone, or by teeth in combination with other oral tissues (1). The American Board of Forensic Odontology description of a typical human bite involves a circular patterned injury consisting of opposing U-shaped arches separated at their bases. Within each arch, there may be a series of wounds that exhibit characteristics of the inflicting dentition. These wounds may manifest as abrasions, contusions, or lacerations. Due to the forces applied, movement of both teeth and skin during the biting action, and individual variations in the response to the skin injury, it is common for there to be departure from the "typical" pattern. Central ecchymoses, linear abrasions, partial arch marks and indistinct bruising are regularly encountered (2).

Recognition of injuries as bite marks, and the subsequent analysis to identify or eliminate suspects, is an important function of the specialist forensic odontologist. Given that assessment of bite mark injuries must include the possibility that a dentition was not the cause of the injury, there is a surprising paucity of references in the literature describing alternative causes for annular injuries. Goodbody et al. (3) mentioned saw marks as a potential source of injury, while Grey (4) reported a case where three injuries were eventually attributed to a defibrillator. Gould et al. (5) discussed dermatoses such as subacute cutaneous lupus erythematosus, pityriasis rosea, dermatophytosis and granuloma annulare that require differentiation from bite marks. A review of the case files of the Forensic Odontology Unit, University of Adelaide revealed injuries caused by a shoe pattern, seat belt buckle, wheel from a child's toy and clothing belt buckle were all initially notified as possible bite marks.

Case Report

In October 2002, a 42-year-old female presented with an injury to her right buttock, which she alleged to be a human bite mark, made by a member of her own family in the course of an assault. Initial police action involved photographing the injury and referral to the

local Sexual Assault Unit for medical examination. Subsequently, a formal examination by a forensic odontologist was requested.

The injury consisted of a semi-circular pattern of healing abrasion measuring 24 mm by 14 mm, surrounded by diffuse bruising (Fig. 1). Due to the size and arrangement of the injury, it was concluded that the mark was not caused by human teeth. The orientation of the injury was also inconsistent with the history offered by the victim. Other causes for the pattern injury were then considered.

To further assist in the investigation a photograph of the injury pattern was selected. Using an Arcus 1200 Agfa^R scanner, and a personal computer with Adobe^R Photoshop^R 6.0 software, the photograph was aligned and resized using the techniques described by Bowers and Johansen (6) (Fig. 2). The same equipment was used to scan a corrugated bottle top. A digitally produced overlay image of the edging of the bottle top was constructed (Fig. 3), and the computer-generated overlay was compared with the injury pattern on the photograph (Fig. 4). There was good correlation between the two images. It is possible that the bottle top was used to self-inflict the injury.

In view of the results of the odontological examination, police did not proceed with any further investigation and no formal charges were made.

Discussion

The use of teeth to mark the skin has been well documented (7–9). Teeth may be used as either offensive and defensive weapons, with bite marks cited in cases of physical or sexual assault, child abuse, and homicide (10). Given the gravity of such crimes, it is important to recognize that bite marks may also be produced by consensual acts, by accident, or by self-injurious behavior.

Equally, many semi-circular marks are not produced by teeth. ABFO guidelines (11) are clear that marks should be assessed to determine the degree of confidence with which it can be stated that the injury is a bite mark, i.e., possible, probable, or definite bite marks. Recognition of injury patterns as human bite marks is a concept that is promoted to general practitioners and law enforcement officers. It is the role of the forensic odontologist to determine

¹ Forensic Odontology Unit, University of Adelaide, SA 5005, Australia.
Received 10 May 2003; and in revised form 10 Aug. 2003; accepted 14 Aug. 2003; published 17 Dec. 2003.

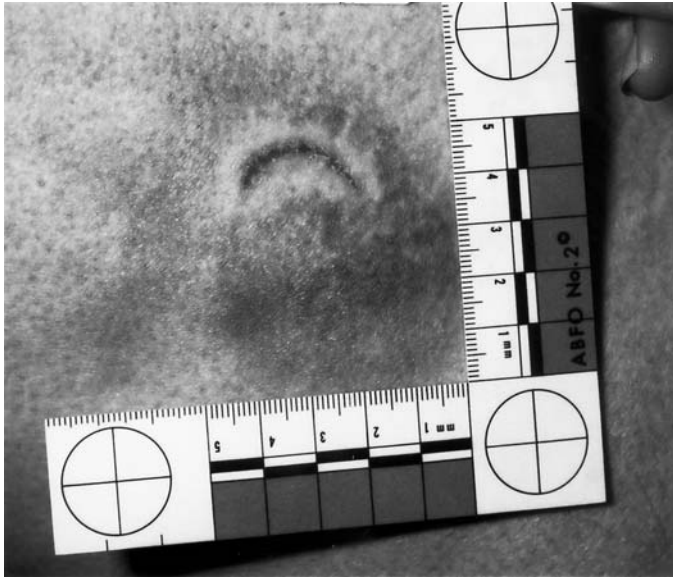


FIG. 1—Original photograph of injury (with ABFO No. 2 scale)




FIG. 3—Corrugated bottle top, with computer-generated overlay of edging (with ABFO No. 2 scale)

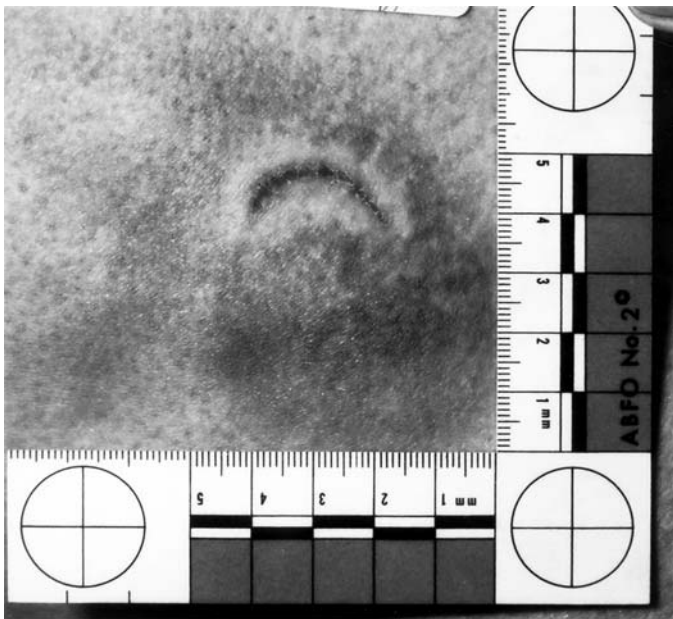


FIG. 2—Corrected photograph (with ABFO No. 2 scale)

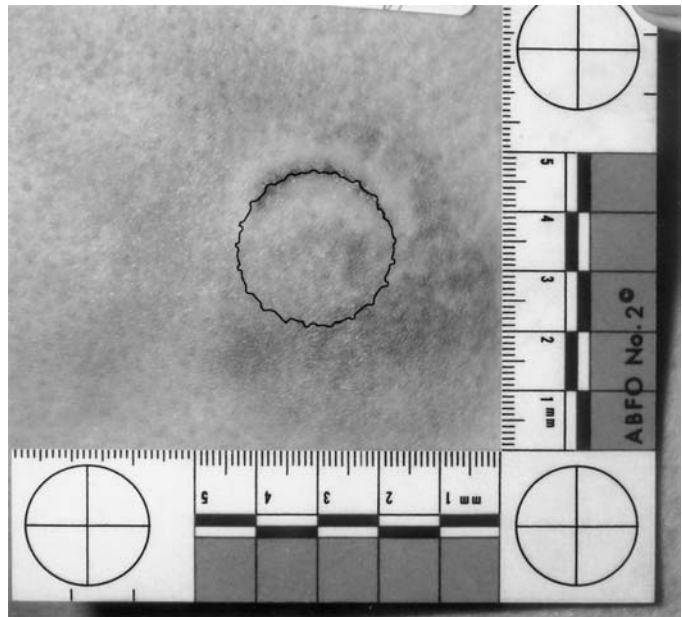


FIG. 4—Hollow volume overlay of bottle top superimposed onto the injury (with ABFO No. 2 scale)

if the injury has been caused by teeth or is merely mimicking a bite mark. As far as the authors are aware, there has been no previous literature reference to bottle tops being used to simulate an alleged human bite mark.

Acknowledgments

The authors acknowledge the support of both the Minister for Police in South Australia and the South Australian Police.

References

1. Whittaker DK, MacDonald DG. A colour atlas of forensic dentistry. London: Wolfe Publishing Ltd, 1989.
2. Sweet DJ. Bitemark evidence. Human bitemarks: examination, recovery and analysis. In: Bowers CM, Bell GL, editors. Manual of forensic odontology, 3rd ed. Colorado Springs, CO: American Society of Forensic Odontology 1997;148–69.
3. Goodbody RA, Turner CH, Turner JL. The differentiation of toothed marks: report of a case of special forensic interest. *Med Sci Law* 1976; Jan (1):44–8.
4. Grey TC. Defibrillator injury suggesting bite mark. *Am J Forensic Med Pathol* 1989;10(2):144–5. [\[PubMed\]](#)
5. Gold MH, Roenigk HH, Smith ES, Pierce LJ. Human bite marks: differential diagnosis. *Clin Pediatr* 1989;28(7):329–31.
6. Bowers CM, Johansen RJ. Digital analysis of bite marks and human identification. *Dent Clin North Am* 2001;45(2):327–42. [\[PubMed\]](#)
7. Gustafson G. Forensic odontology. London: Staples Press 1966;140–65.
8. Sopher IM. Forensic dentistry. Springfield: Charles C Thomas, 1976; 125–52.
9. Wright FD, Dailey JC. Human bite marks in forensic dentistry. *Dent Clin North Am* 2001;45(2):365–97. [\[PubMed\]](#)
10. Sweet D, Pretty IA. [A look at forensic dentistry—Part 2: Teeth as weapons of violence— identification of bitemark perpetrators.](#) *Br Dent J* 2001;190(8):415–8. [\[PubMed\]](#)
11. American Board of Forensic Odontology. ABFO Guidelines and Standards. In: Bowers CM, Bell GL, editors. Manual of forensic odontology, 3rd ed. Colorado Springs, CO: American Society of Forensic Odontology, 1997;299–357.

Additional information and reprint requests:
 Helen James
 Forensic Odontology Unit
 University of Adelaide SA 5005
 Australia